SEPARC
Information Sheet #5

AN ALVEOLATE AGENT IN SOUTHEASTERN AMPHIBIANS

By: Joshua O. Cook

Amphibian Die-offs:

Widespread infection by an emerging alveolate pathogen, referred to by some as the *Perkinsus*-like agent or *Dermomycoides* sp., has caused mass mortality of amphibians throughout the United States. The pathogen was first documented in New Hampshire by David E. Green in 1999 (1), and since then infections have been reported in seven additional states (Florida, Mississippi, Georgia, Virginia, Minnesota, Alaska, North Carolina, and Maine). Mass mortality associated with this pathogen has occurred in Mississippi, New Hampshire, Virginia, Minnesota, Florida, and Georgia (1, 2, 3, 4). This *Perkinsus*-like agent has been documented primarily in tadpoles of true frogs (Family Ranidae); however, infections have also occurred in adult and larval treefrogs (Family Hylidae) and adult ranids (1, 3). Known infections by this agent have been reported in the wood frog, southern leopard frog, bullfrog, mink frog, green frog, Mississippi gopher frog, and spring peeper (1, 2, 4). Mass mortality of the Mississippi gopher frog is of particular concern as it is one of the rarest anurans in North America, with about 100 known adults remaining in the wild. Thus, this pathogen may pose a significant risk to Mississippi gopher frog populations and perhaps other frogs in the southeastern United States. The recent documentation of this pathogen among frogs in the United States suggests its recent emergence.

Pathogen Characteristics:

The life history of the alveolate pathogen remains unresolved and no transmission or experimental infection studies have been published to date (although see reference 3).

Diagnostics and Signs of Disease:

Infections by this alveolate can be seen microscopically as spherical to sub-spherical spores, which measure 6.2 µm ± 0.3 in length and 5.5 µm ± 0.4 in breadth (Figure 1; 2). Spores have a thick cell wall with polyhedral surface structuring and contain either a single inclusion body or multiple smaller granular bodies (2, 3). The pathogen can infect multiple organs. Individuals with spores restricted to the intestine rarely exhibit any gross signs of disease. Diseased individuals typically have systemic infections, with spores present in the intestines, liver, spleen,

kidney, somatic muscle tissue, skin and mesentery. Diseased tadpoles often appear lethargic and sometimes are bloated and have hemorrhaging of the skin (Figure 1), which also are gross signs associated with fungal or viral infections (2, 3). The liver of diseased individuals often appears severely distended and whitish in color (1, 2). Necrosis of the liver and kidney tubules occurs in terminal stages (1,2).

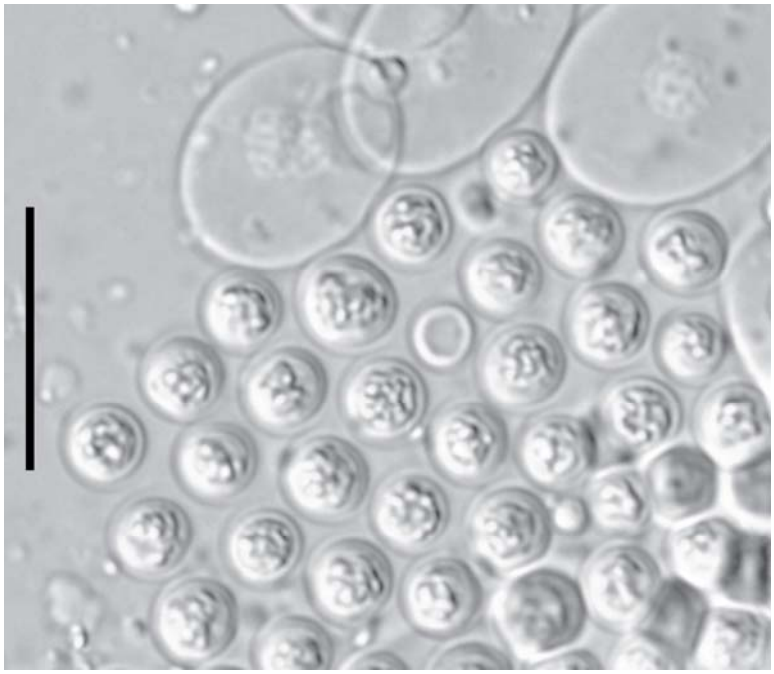

Figure 1. Spores of the alveolate pathogen harvested from the liver of a diseased southern leopard frog tadpole. Scale bar = 20 µm.

Figure 2. A southern leopard frog tadpole infected with the alveolate pathogen exhibiting skin hemorrhages.

References

1. Green, D. E., S. H. Feldman, and J. Wimsatt. 2003. Emergence of a *Perkinsus*-like agent in anuran liver during die-offs of local populations: PCR detection and phylogenetic characterization. Proceedings of the American Association of Zoo Veterinarians 2003:120-121.
2. Davis, A. K., M. Yabsley, K. Keel, and J. C. Maerz. 2007. Discovery of a novel pathogen affecting southern leopard frogs in Georgia: description of the disease and host effects. EcoHealth 4:310-317.
3. Cook, J. C. 2008. Transmission and occurrence of *Dermomycoides* sp. in *Rana sevosa* and other ranids in the North central Gulf of Mexico states. Thesis. University of Southern Mississippi, Hattiesburg.
4. Gahl, M. K. 2007. Spatial and temporal patterns of amphibian disease in Acadia National Park wetlands Dissertation, University of Maine, Orono.

Author's Affiliation and Contact Information:

College of Veterinary Medicine
University of Georgia
joshcook@uga.edu
228-369-0548

Recommended Citation:

Cook, J. O. 2009. An alveolate agent in southeastern amphibians. Southeastern Partners in Amphibian and Reptile Conservation, Disease, Pathogens and Parasites Task Team, Information Sheet #5.

Reviewed and edited by Dr. Matt Gray and Dr. Debra Miller (co-chairs of the Disease, Pathogens, and Parasites Task Team of Southeastern PARC).